

Thyroid ophthalmology (Grave's disease)

Thyroid eye disease, Grave's ophthalmopathy, dysthyroid ophthalmopathy, and Grave's disease are all synonymous terms connoting a process that is clinically characterised by eyelid retraction, proptosis, conjunctival exposure, ocular injection, ocular chemosis, corneal compromise, extraocular muscle infiltration and fibrosis with the potential for compressive optic neuropathy¹⁻⁵. It is the most common cause of bilateral, symmetric proptosis in adults⁵.

Pathophysiology

McKenzie has provided the most pragmatic definition of Grave's disease as a multisystem disorder of unknown etiology, characterised by one or more of the following three clinical entities:

1. Hyperthyroidism associated with diffuse hyperplasia of the thyroid gland;
2. Infiltrative ophthalmopathy; and
3. Infiltrative dermopathy (pretibial myxedema)³.

The histopathologic features of the malady include an infiltration of the thyroid gland, skin, extraocular muscles and orbital fat by lymphocytes, macrophages, plasma cells, mast cells and mucopolysaccharides^{3,5}. These changes are characteristic of but not limited to an immunologically mediated mechanism³.

Signs and symptoms

Interestingly, ocular findings may occur independently from dysthyroid function, being more severe, less severe or matching the systemic condition¹⁻⁵. Euthyroid Grave's disease is a condition where the characteristic ophthalmic manifestations of thyroid eye disease exist in the presence of a clinically and biomedically normal thyroid gland^{1,3}.

Most patients with ocular Grave's disease manifest systemic hyperthyroidism. Up to 80% of patients with systemic hyperthyroidism develop some eye signs⁵. Some of the systemic signs of hyperthyroidism include weight loss despite increased appetite, nervousness, palpitations, tachycardia while at rest, systemic hypertension and hyperreflexia^{1,3}. Conversely, lethargy, bradycardia and weight gain despite decreased appetite are signs of hypometabolism and potential hypothyroidism³.

In 1969, the American Thyroid Association adopted the formal classification of Ocular Grave's disease, represented by the mnemonic NOSPECS^{1-3,5}. The disease process passes through six stages from no signs or symptoms present, 1, Only symptoms of ocular irritation (dryness, tearing, foreign body sensation), 2, Soft tissue involvement (periorbital oedema), 3, Proptosis, 4, Extraocular muscle involvement (eye motility problems, diplopia), 5, Corneal involvement (dense S.P.K., S.E.I.'s, ulcerations), 6, Sight loss with or without visual field compromise secondary to compressive optic neuropathy^{1-3,5}.

However, because the disease is recognised as variable, in 1974, the formal classification was revised to range from no manifestations to mild, moderate or severe manifestations⁵.

Figure 1: Thyroid Eye Disease

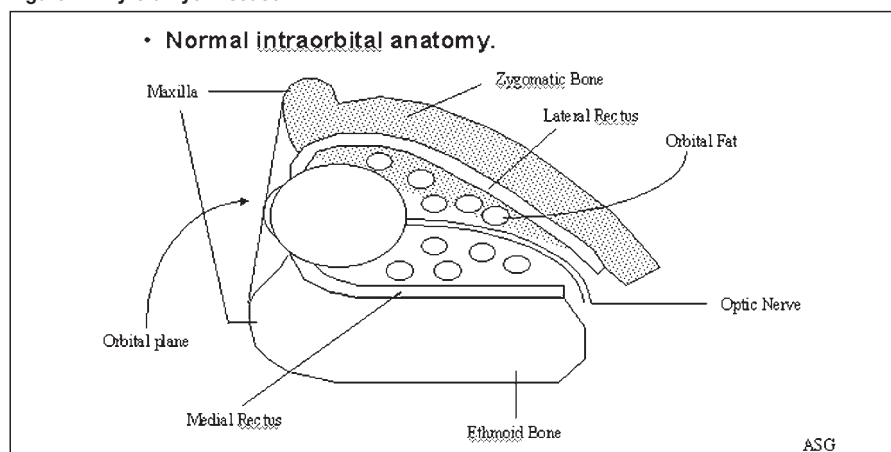
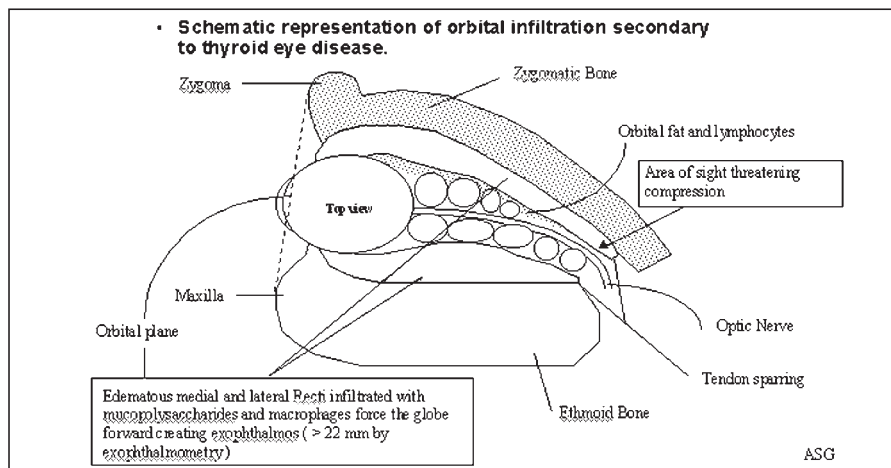


Figure 1a: Thyroid Eye Disease



The common, clinically diagnostic eye signs include:

- von Graefe's sign (*superior lid lag upon down gaze*)
- Dalrymple's sign (*eyelid retraction*)
- Stellwag's sign (*infrequent blinking*)
- Ballet's sign (*Palsy of one or more extraocular muscles*)^{1, 5}.

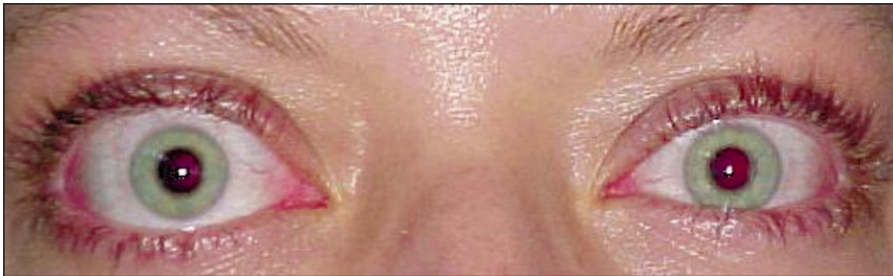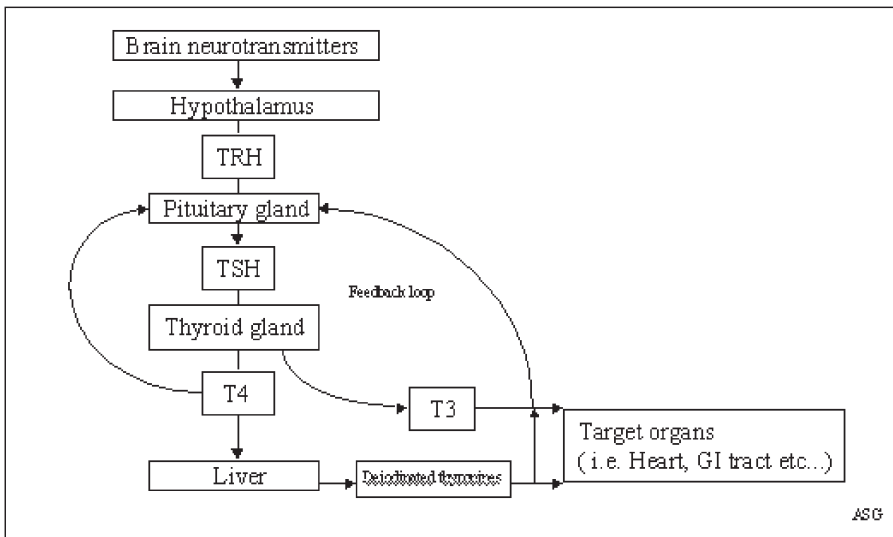
Management

The diagnosis of Grave's disease can often be made easily, based on symmetrical exophthalmos (exophthalmometry > 22mm or asymmetry greater than 3mm) and lid

retraction in the presence of known hyperthyroidism. If symptoms are present and a systemic aetiology has not been investigated, consultation with a neuro-ophthalmic specialist and laboratory testing for thyroid hormones T3 (triiodothyronine), T4 (tetraiodothyronine) and TSH (thyroid-stimulating hormone) are indicated.

The systemic management of patients with ocular Grave's disease lies in the domain of the endocrinologist or neuro-ophthalmic specialist. Agents that block the synthesis of thyroid hormone such as propylthiouracil (Tapazole) or decrease hypermetabolic symptoms such as propranolol (Inderal) have been proven effective^{1,3}. Systemic steroids, immunosuppressive agents like azathioprine,

Figure 2: Schematic representation of the thyroid axis



cyclosporin or cyclophosphamide in combination with orbital irradiation have shown promise in advanced cases^{1,5}. Today, surgical decompression procedures (Kronlein and Ogura) are a last resort.

Since the primary difficulty, proptosis and lid retraction, presents as corneal exposure, ocular management is predominantly supportive. Moistening the cornea with artificial tear drops and ointments, as necessary is typically effective. Moisture shields (Eagle vision) that can be attached to the temples of spectacles help to preserve tears and retard tear evaporation. Punctal plugs may be effective for increasing the lacrimal lake. Cases that involve moderate to severe signs and symptomatology may require topical antibiotics^{1,3}. Visual fields should be performed on patients with advanced stage disease, monitoring for the first sign of sight or field loss. Recall is usually every three to six months and is based upon a patient's severity.

Since a variety of neuro-ophthalmic entities deserve consideration in diseases where there is proptosis or malposition of the eyelid (Myasthenia gravis, Illusory ptosis of the opposite eyelid, neoplasm, arteriovenous malformation, carotid cavernous fistula, infection, inflammation) forced duction testing (positive in Grave's) and neuro-imaging (MRI or CT showing

enlarged EOM bellies with tendon sparing = Grave's) should be completed^{1,5}. If myasthenia is suspected a tensilon test should be ordered. Occasionally A and B scan ultrasonography are useful for evaluating fluid in the vicinity of the optic nerve^{1,3,5}.

References

1. Gurwood, A.S. (1994) Endocrine Disease. In: Blaustein, B.H. *Ocular Manifestations of Systemic Disease*. New York, NY: Churchill Livingstone 117-148.
2. Gurwood, A.S. (1992) *The Eyelid and Neuro-ocular Disease*. In: Blaustein, B.H. *Ocular Manifestations of Neurologic Disease*. Philadelphia, PA; J.B. Lippincott Co.; 4(3), 438-53.
3. Sergott, R.C., Glaser, J.S. (1981) *Grave's Ophthalmopathy: A Clinical and Immunologic Review*. Survey of Ophthalmology; 26(1), 1-21.
4. Kazim, M., Trokel, S., Moore, S. (1991) *Treatment of Acute Grave's Orbitopathy*. Ophthalmology; 98(9), 1443-47.
5. Liu, D., Feldon, S.E. (1992) *Thyroid Ophthalmopathy*. Ophthalmology Clinics of North America; 5(3), 597-622.